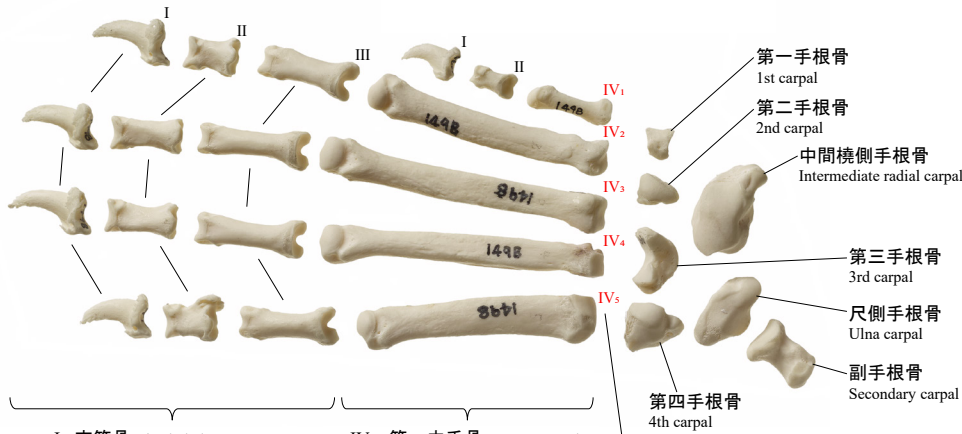


イヌの手骨格・足骨格

Dog Hands and Feet

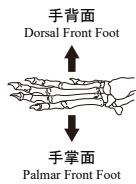
前肢(左) Front Foot(L)

手背面
Dorsal Front Foot

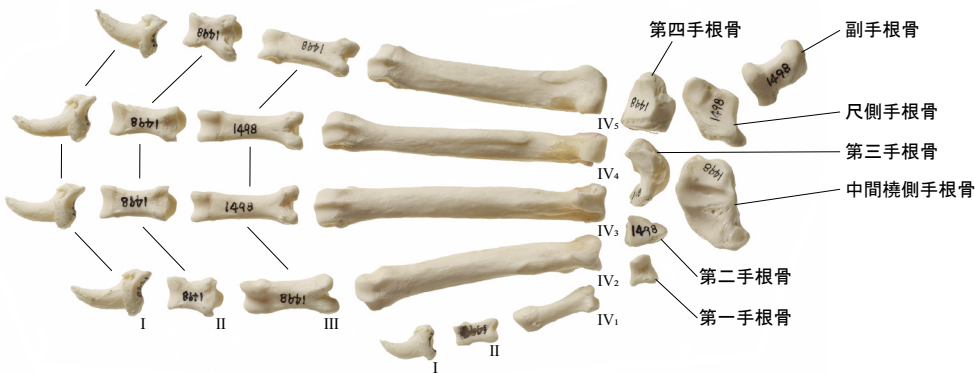


I : 末節骨 Distal phalanx
II : 中節骨 Middle phalanx
III : 基節骨 Proximal phalanx

IV₁ : 第一中手骨 1st metacarpal
IV₂ : 第二中手骨 2nd metacarpal
IV₃ : 第三中手骨 3rd metacarpal
IV₄ : 第四中手骨 4th metacarpal
IV₅ : 第五中手骨 5th metacarpal

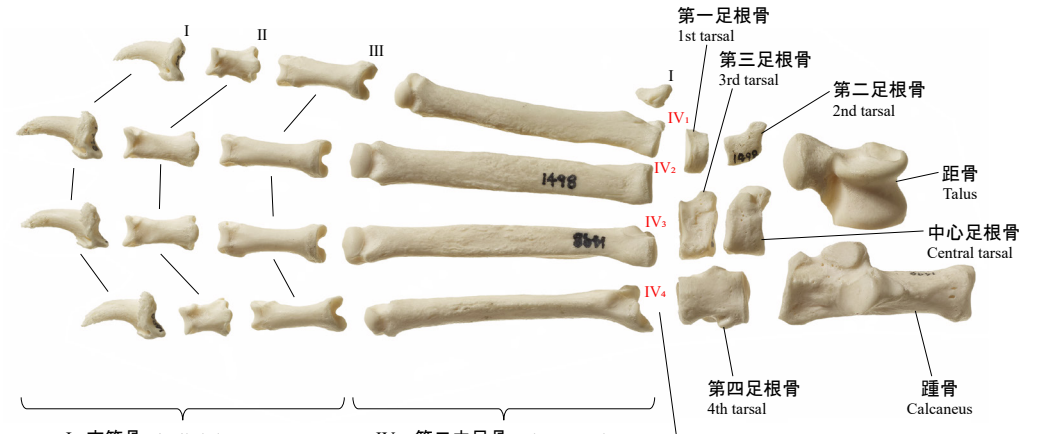


手掌面
Palmar Front Foot



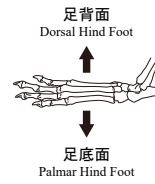
後肢(左) Hind Foot(L)

足背面
Dorsal Hind Foot

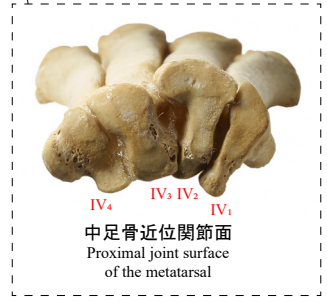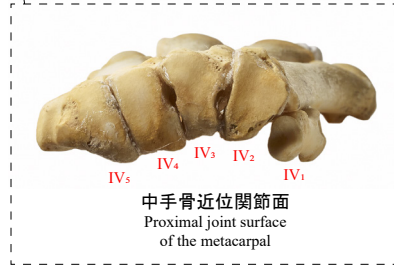
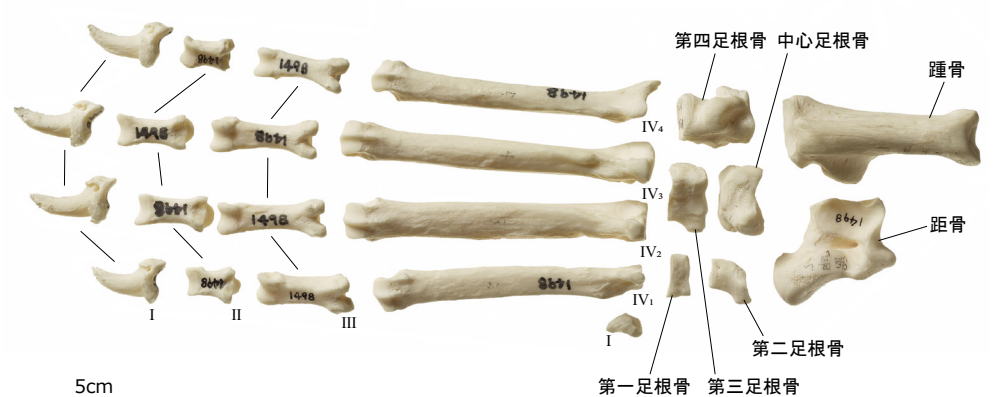


I : 末節骨 Distal phalanx
II : 中節骨 Middle phalanx
III : 基節骨 Proximal phalanx

IV₁ : 第二中足骨 2nd metatarsal
IV₂ : 第三中足骨 3rd metatarsal
IV₃ : 第四中足骨 4th metatarsal
IV₄ : 第五中足骨 5th metatarsal



足底面
Palmar Hind Foot



5cm